

YOUNG SCIENTIST

APRIL 2023

LET YOUR DREAM
TURN INTO AN ARTICLE!



Dental implants and single implant-supported restorations

Item Type	Article
Authors	Jumayev Hojamemmet Jumayevich, Garayev Bayramnyyaz Tachmuhammedovich, Serdarov Begench Atayevich
Publisher	Young Scientist
Download date	11/06/2025 20:10:54
Link to Item	http://youngscientist.xyz

Find this and similar works at - <http://www.youngscientist.xyz>



Jumayev Hojameemet Jumayevich

Head of the Department of Postgraduate Training in Dentistry of the State Medical University of Turkmenistan named after Myrat Garryev, Doctor of Medical Sciences



Garayev Bayramnyyaz Tachmuhammedovich

Assistant of the Department of Postgraduate Training in Dentistry, Myrat Garryev State Medical University of Turkmenistan



Serdarov Begench Atayevich

Assistant, Department of Postgraduate Training in Dentistry, Myrat Garryev State Medical University of Turkmenistan.

Dental implants and single implant-supported restorations

Abstract: Replacing missing teeth using dental implants is a good treatment option with a high degree of success. As the dental implantology field develops and the number of implants placed worldwide increases, several terms and techniques have been formulated. Therefore, a basic knowledge of dental implants is necessary for every dental student and dentist. The current article sheds light on how the dental implant integrates with its surrounding bone and what factors can affect this integration. The relationship between the implant and its surrounding soft tissue, different types of the dental implants, and the restorative components and procedures, are all reviewed.

Key terms: osseointegration; single dental implant ; single implant abutment; screw-retained; restoration; cement-retained restoration.

Journal of the Irish Dental Association 2025; 59 (1): 32-43.

Introduction

The use of dental implants in replacing single and multiple missing teeth is proven to be a valid treatment with a high success rate.¹ To achieve the best treatment outcome in all implant systems, the implant has to be able to integrate with its surrounding tissue.

Several clinical studies have reported that, under optimum circumstances, a long-term rigid union between the implant surface and the surrounding bone can be achieved and maintained for indefinite periods of time.^{2,3}

Therefore, to maintain the rigid union, continuous remodelling of the bone supporting the implant in the presence of functional loading is essential. However, this integration is highly affected by several factors, such as bone quality, quantity and the implant loading condition.^{1,2}

In general, dental implants usually consist of the implant body and the abutment to which the restorations are attached. To attach the restorative counterpart to the implant, an impression has to be made. The impression technique here is similar to that used in conventional prosthodontics work.

There are a variety of dental implant systems, and several terms and techniques have emerged with the use of dental implants. Some of these terms are confusing and knowing all of the terms and techniques is not easy.

This article provides clarification of the terms used in dental implantology, as well as an overview of the subject area, both of which are vital for every dental student and dentist.

Background

Bone-implant contact and osseointegration

The connection between implant surfaces and bone can be mediated by either connective tissue fibres or by intimate contact of bone and implant surface. While the former indicates a failure of any implant system, the latter is the objective of the implant surgery and is known as osseointegration. Commencement of either mechanism is influenced by many factors, which will be discussed later.^{4,5}

Light microscopy of histological studies on retrieved osseointegrated and failed implants in humans and some animals revealed that

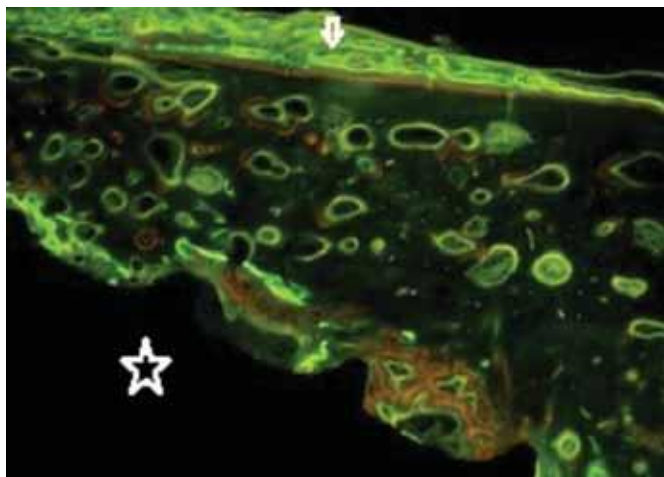


FIGURE 1: Fluorescence of a ground section three months after implant placement in a dog mandible. Bone remodelling and new bone formation can be seen, as indicated by the different chelating agents that were injected at different times during the three-month healing period. The implant is indicated by the white star and subperiosteal new bone formation by the arrow.

successful osseointegration shows direct apposition of bone on implant surface (**Figure 1**). However, Sennerby and co-workers⁶ used an electron microscope to study the nature of the oral implant-bone interface of seven clinically stable “osseointegrated” titanium implants inserted in human jaws for one to 16 years, and concluded that the peri-implant bone was separated from the implant surface by an amorphous layer, 100-400nm in depth.⁶ Bone is a load-bearing material that is able to adapt its inner structure and architecture to its mechanical environment.^{7,8} This ability is controlled with a specific feedback mechanism that is not fully understood.⁹ When the bone around the implant is loaded, its reaction to this load may take one of two routes depending on the load level. First, when the load is within the physiological limit, the bone will be stimulated to remodel and maintain its integrity, as continuous remodelling activity around the implant has been reported to occur. Second, when the loading level exceeds the physiological limit, excessive bone resorption occurs and consequently the implant fails.¹⁰ Failure of oral implants as a result of occlusal overloading has been reported and experimentally demonstrated in animals. Excessive occlusal force on endosseous oral implants can result in complete or partial loss of osseointegration, with a narrow zone of soft tissue between them.¹⁰ This may be attributed to microdamage in the bone surrounding the implant, which exceeds the repair potential of this bone and leads to the replacement of bone-implant interface with soft tissue. However, as the occlusal forces are difficult to quantify and most of the studies were conducted on animals, this makes drawing a strong conclusion on this matter difficult. Nevertheless, it is important to mention that generation of micro-cracks in the peri-implant bone was reported to occur during implant placement as well as during function. Therefore, in order to repair this damage and to maintain osseointegration, bone needs to constantly remodel.¹¹

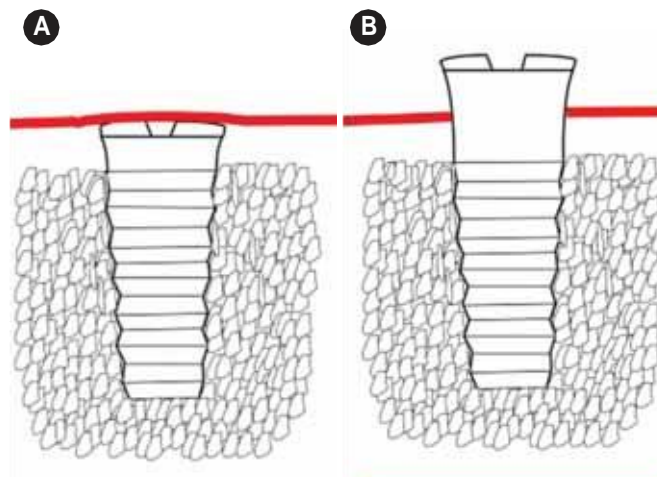


FIGURE 2: A schematic presentation of an implant placed according to the two-stage (a) and one-stage (b) implant placement methods. Note the trans-mucosal (the neck) part penetrating the overlying soft tissue in the one-stage method.

Implant-soft tissue interface

Several studies have reported that the soft tissue that surrounds an implant has similar features to the soft tissue that surrounds teeth.^{12,13} Therefore, the peri-implant soft tissue consists of a junctional epithelium, which is attached to the implant or abutment surface through a hemi-desmosomal attachment. Apical to the junctional epithelium and coronal to the crest of alveolar bone, there is an area of connective tissue, which is in contact with the implant surface. Collagen fibres arise from the crest of alveolar bone and periosteum and are oriented parallel to the implant surface towards the oral epithelium. Circular and horizontal fibres, which run perpendicular to the implant surface, were also found in the area.¹³ It seems that the implant-soft tissue interface makes a protective seal between the oral environment and the bone, which plays a vital role in the success of the implants.

Implant placement techniques and the placement time

Implant placement techniques can be classified as two- or one-stage procedures. In the two-stage technique (also known as the submerged technique) two surgical interventions are required. The first involves installing the implant body into the bone. A cover screw is then attached to the implant platform and covered by oral mucosa (**Figure 2a**). After three to six months, the second intervention occurs where the implant is exposed surgically and a healing abutment is attached. Thus, the abutment is completely separated from the implant body. The implant system used with this surgical method is usually a two-piece implant. This surgical approach allows the pre-implant tissue to heal without loading. It is suitable for use with most clinical situations, particularly when the implant placement is associated with bone grafting and when the quality of bone is not optimum. Examples of an implant system used for the two-stage

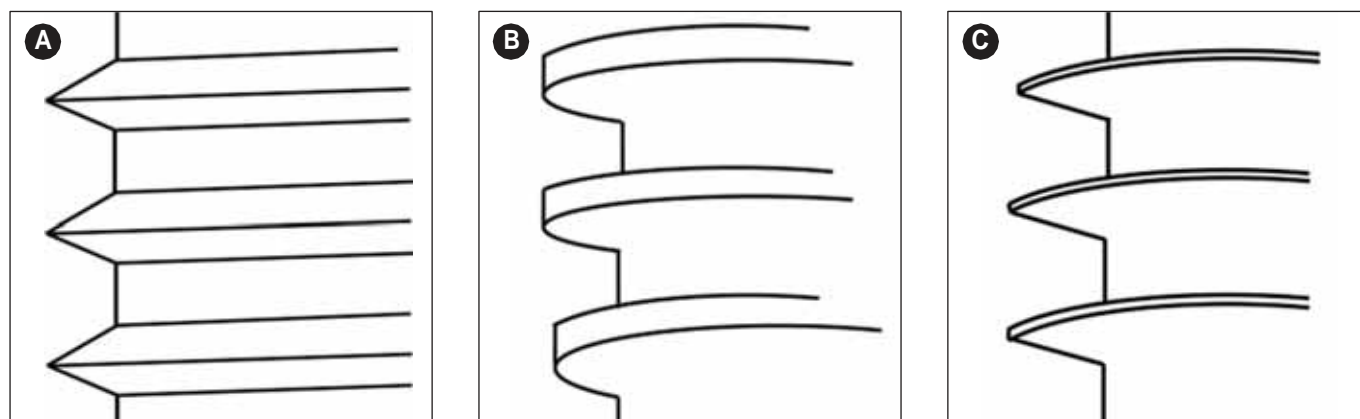


FIGURE 3: A representation of the most commonly used implant threads: a) v-shaped thread; b) square thread; and, c) a reverse buttress (modified from Todd et al., 1998).²⁴

procedure include the Fixture MK III® (Nobel Biocare), MAX 2.5® Implant (Bicon) and OSSEOTITE® 2 Certain Implant (Biomet 3i).

In the one-stage technique (also known as non-submerged), the coronal part of the implant is positioned above the crest of the alveolar bone, passed through the peri-implant soft tissue, and is left uncovered and exposed to the oral environment during the healing process (Figure 2b). In this technique, a restoration can be attached immediately to the implant or it may be attached later. With this surgery protocol, a one/two-piece implant system can be applied. Examples of the implants that can be placed using the one-stage technique include the Solid-Screw Implant® (Straumann), AdVent® Implant (Zimmer) and Single-stage Implant System® (BioHorizons).

Several studies have shown that the one-stage technique has some clinical advantages when compared with the two-stage method. These advantages include:

- (i) the avoidance of a second surgical procedure;
- (ii) the lack of a micro-gap at the bone crest level, resulting in a less crestal bone resorption;
- (iii) the prosthetic procedure is simplified and less chair time per patient is required; and,
- (iv) a non-loaded, immediate or delay-loaded protocol can be implemented.¹² Nevertheless, both surgical protocols can be clinically successful.¹⁴

The time at which the implant is placed after extraction of the tooth/teeth may be categorised as immediate, immediate-delayed and delayed.¹⁵ Immediate is when the implant is inserted into a socket just after tooth extraction. Immediate-delayed placement is when the implant is placed weeks to a few months after tooth extraction, while delayed placement is when the implant is introduced thereafter.¹⁵ With the immediate and immediate-delayed implant placement, the treatment time is shortened and the risk of bone resorption may be minimised. However, the risk of infection and its resulting implant failure cannot be overlooked.^{15,16} Nevertheless, immediate implant placement may be the preferred choice for a good aesthetic outcome. When the implant is immediately placed after tooth extraction, a gap

between the implant and the surrounding bone exists. This can be dealt with using bone augmentation techniques if required.

In conclusion, immediate implant placement may reduce bone resorption and preserve the crestal bone, which will improve the aesthetic outcome. However, factors such as a gingival tissue biotype, thin alveolar bone and the bucco-lingual position of the implant all have a strong effect on the potential bone resorption and gingival recession. Thus, good communication between the prosthodontist and the surgeon who will install the implant is important in order to achieve the best possible outcome.

Factors affecting osseointegration

Several factors have been found to affect osseointegration. These factors include: material biocompatibility; surface macrostructure (design) and microstructure (roughness); heat generation during the implant placement surgery; initial implant stability; bone quality; surgical technique; and, loading conditions.²

Material biocompatibility

Biocompatibility is the ability of a material to perform a suitable response in a specific environment.¹⁷ Reaction of peri-implant bone, resulting in osseointegration, is an example of material compatibility. On the other hand, incompatible materials are usually encapsulated by a thick connective tissue and these materials will eventually be rejected by the body.

The most commonly used materials in dental implants are either bio-inert, such as commercially pure titanium (CP titanium) and titanium alloy, or bioactive ceramics such as hydroxyapatite (HA).¹⁸

Titanium is a non-noble metal that has the ability to form a very adherent self-repairing and protective surface oxide layer that prevents further titanium corrosion. It is used in oral implants in a pure form (99.75% pure) and as an alloy (Ti-6-AL-4V alloy) (90% Ti, 6% AL and 4%V). Available literature indicates that CP titanium has a successful long-term performance.

Ceramics are a compound made of a mixture of metals and non-metals. An example of a ceramic material is HA, a calcium phosphate.

It has been claimed that HA is capable of forming a direct biochemical bond with bone due to their similar chemical composition.¹⁹ HA is used as an implant material to repair bone defects. It has also been used as an implant coating material due to its ability to accelerate bone healing and improve bone apposition around HA-coated implants as compared with titanium implants, resulting in better implant-bone integration.²⁰ Furthermore, the bone around the HA-coated implants was found to be more complete and more uniform than that formed around the CP titanium implant.²¹ However, HA has poor mechanical properties and has therefore been used as a coating attached to the implant titanium substrate.²² The possibility of its fragmentation and detachment from the substrate is a real problem that precludes its use in dental implants.

Implant design (surface macrostructure)

Implant design is one of three important reported factors on which implant primary stability depends.²³ Implant primary stability plays a major role in achieving osseointegration.^{2,23} Currently, screw-shaped (threaded) implants are the most commonly used implant designs, while smooth cylinder implants (press-fit) are eliminated. In an experimental study on dogs, screw implants were found to have a better bone anchorage than the cylindrical implants.²⁴

The most commonly cited thread shapes are v-shaped, square shaped or reverse buttress²⁵ (Figure 3). The threads are usually incorporated into the implant design to improve the initial stability and dissipate interfacial stress in a more favourable way. Thread features such as thread depth, thread thickness, face angle, pitch and helix angle are considered as factors that determine the functional thread surface and affect the biomechanical load distribution of the implant. The functional thread surface is that part of the thread which allows dissipation of compressive and tensile loads to the bone in a constructive manner.²⁶

Implant surface texture

Implant surface texture is found to positively affect the healing of peri-implant tissue. The implant surface is usually roughened to increase its surface area, which is reported to encourage bone healing and provide long-term implant stability, particularly in areas with low bone density. In general, two methods for alteration of implant surface roughness (texture) have been described in the literature: additive or subtractive. In the former method, a biocompatible material such as titanium plasma-sprayed coating is added to the implant surface substrate,²⁷ while in the second some material is removed from the implant surface by blasting and/or acid etching.^{27,28}

There is a general agreement that implants with rough surfaces exhibit an increase in implant bone contact when compared with the machined, smooth-surface implants. In one study by Lazzara and associates,²⁹ the amount of peri-implant bone for acid-etched implant rough surfaces and machined surfaces was estimated to be 72.96% and 33.98%, respectively.²⁹ However, exposure of the rough implant surface may facilitate plaque accumulation, which could be difficult to remove and will lead to infection and endanger the implant.¹⁰

Heat generation during the implant placement surgery

Controlling the heat generated during implant surgery is important in order to achieve uneventful healing and to allow osseointegration.³⁰ During the osteotomy preparation (surgically prepared implant site), heat-induced bone damage may occur due to overheating of surrounding bone. This may lead to bone necrosis, an inflammatory infiltrate and the formation of fibrous tissue between the implant and the bone. These events may ultimately result in implant failure.³¹ The critical temperature that can damage bone was estimated to be 47°C for one minute, as at this temperature the bone is unlikely to repair the damage.³¹ However, heat is not only generated during the osteotomy preparation but also during implant placement.^{31,32} Bone heating may be generated by excessive pressure on bone during the surgery and pressure applied was found to have more effect on heat generation than the speed of the drill.³³ Thus, heat as well as pressure control during the surgery is needed to achieve osseointegration. Furthermore, it was reported that bone density plays an important role in temperature elevation. These factors should be considered and efforts should be made to reduce and eliminate an increase in the surrounding bone temperature. The use of a coolant during implant surgery is recommended to minimise heat generation and its negative effect. A drill with efficient blades that ensures effective cutting with minimum adverse events is also required to optimise the outcome of the treatment.

Initial (primary) stability

Primary implant stability is the stability of an implant within the osteotomy at the time of implant placement. It is related to the level of the intimate contact between the implant and its surrounding bone.³⁴ It is an important factor in achieving osseointegration and is essential for early implant loading. Immediately after implant installation tips of threads are usually in close contact with bone, providing initial stability for the implant. However, the implant surface may not be completely in contact with the bone and spaces may exist. These spaces are initially filled with blood that comes from injured blood vessels forming a fibrin network.³⁵

Micro-movement of the implant within the osteotomy has a negative effect on the osseointegration. The acceptable range of movement is reported to be between 50 and 150µm since beyond this range implant failure is more likely to occur.³⁶

Implant length, diameter, design, surface roughness, bone quality and quantity, and surgical technique are reported to play a major role in implant primary stability.^{23,37} All these factors should be considered when an implant is selected. Under-sizing the osteotomy and the use of self-tapping implants may help in achieving primary stability in certain situations such as when bone is soft (type iv). Furthermore, engaging the lower cortex of the mandible or the inferior cortical plate of the maxillary sinus or the nasal cavity may be used to aid implant stability.³⁸

Bone quality

Bone is generally classified as either compact (cortical) or cancellous

(trabecular). Both types differ in their detailed configuration, but have the same basic histological structure. The microstructural unit of cortical bone is known as the osteon (Haversian system) and that of cancellous bone is known as a trabecular packet (hemi-osteon).³⁹ In the dental implant field, the most commonly used bone quality assessment is that described by Lekholm and Zarb (1985).⁴⁰ This method is based on radiographic assessment as well as the resistance during the implant drilling procedure.⁴ According to these authors, bone is categorised into four classes as follows:

- type I: almost the entire bone is composed of homogenous compact bone;
- type II: a thick layer of compact bone surrounds a core of dense trabecular bone;
- type III: a thin layer of cortical bone surrounds a core of dense trabecular bone; and,
- type IV: a thin layer of cortical bone surrounding a core of low-density trabecular bone.

Several long-term clinical studies have demonstrated that poor bone quality was accompanied by a higher risk of implant failure. A higher failure rate was reported to occur with implants placed in type IV bone compared with types I, II or III. Also, implants placed in the maxilla have a higher failure rate than implants placed in the mandible, which may reflect the difference in bone quality of the jaws. Jaffin and Berman (1991)⁴¹ found that 35% of implants placed in type IV bone were lost after five years, while only 3% of those implants placed in type I, II or III bone were lost over the same period.

Surgical techniques

As already mentioned, selection of a proper implant system, a protocol that suits the clinical case, atraumatic surgery, control of heat generation, and the use of efficient implant instruments are all important measures required to achieve a satisfactory outcome. All these factors are the responsibility of the personnel who will install the implant.

Implant loading

Depending on the time at which an implant is loaded, implant loading may be classified as immediate, early or conventional loading.^{42,43}

Immediate implant loading: when the implant is exposed to loading earlier than one week following implant placement.

Early implant loading: when loading is applied within one week to two months subsequent to implant placement.

Conventional implant loading: when the load is applied after an unloaded healing period of at least two months subsequent to implant placement.

While an immediate and early loading protocol may be implemented when clinical situations are considered optimum, conventional loading is recommended under specific conditions such as alveolar ridge augmentation and compromised host status.

It has been suggested that conventionally loaded implants have a higher success rate than those implants that are immediately loaded.

Yet the immediately loaded implants less commonly fail than those early loaded. This suggestion indicates that it may be more beneficial to load the implant immediately rather than delaying the loading process;⁴² however, further investigation is required to validate this speculation.

Implant failure

Long-term retrospective and longitudinal studies have provided strong evidence to support high survival rates of osseointegrated implants.^{2,44} However, despite the high survival rates, implant failures do occur. Consequently, implant failures are characterised into two classes: early and late failure. While early failure indicates that failure occurs before the implant is put to function, late failure denotes the failure that occurs months or even years after implant loading. Early failure indicates failure to establish osseointegration, whereas in late failure osseointegration has occurred but has later deteriorated.

Abutment-implant connections

In both implant placement methods (the one- or two-stage), the abutment is connected to the implant body in order to stabilise and prevent rotation of the abutment. The abutment-implant connection can be either external, when it protrudes above the implant platform, or internal, when it is projected down in the access hole in the implant platform. However, different implant producers designed a variety of geometric connection forms including a hexagon, triangle or a tapered cone. In order to improve the stability of the connections, other features may be incorporated.^{45,46} A schematic representation of the external and internal connections is seen in **Figure 4**.

The connection between the mating surfaces of the implant components that are tightened together by a screw is known as the screw joint.^{46,47} In general there are one or two screw joints, depending on whether a cemented or a screw-retained restoration is used. There is always one screw joint between the implant body and the abutment, and if a screw-retained restoration is used there may be another screw joint between the abutment and the restoration.

There are two different forces acting on any screw joint when the screw is tightened: one tries to keep the joint together and is known as the clamping force, and the other tries to disengage it and is referred to as the separating force. As a tightening torque is applied to the screw joint, a tension (pre-load) is generated in the screw. Consequently, the screw shank and threads are placed in tension and an elastic recovery is generated. This elastic recovery creates the clamping force between the mating surfaces.^{46,47} The tension is effective if it is less than the elastic limit of the screw material as no permanent plastic deformation would occur. In order to hold the implant components together and to keep the screw tight, a maximum clamping force and a minimal separating force are required.

Implant components

Implant body

The implant body is the part of the implant that is buried in the peri-

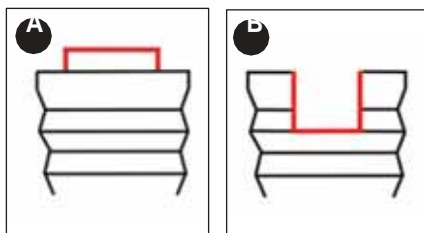


FIGURE 4:
A schematic representation of abutment-implant connections: an external connection (a); and, an internal connection (b).

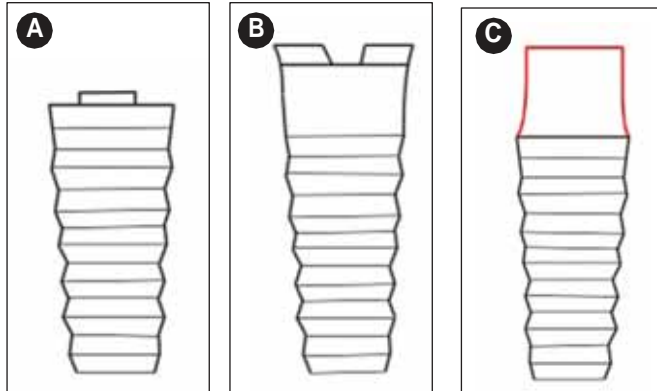


FIGURE 5: A schematic representation of implant types. a and b are examples of two-piece implants; while implant a is used with the two-stage implant placement method, implant b is used with the single-stage method. Implant c represents a one-piece implant system.

implant tissue. It is also known as the implant fixture.⁴⁸ The coronal part of the implant body, which is usually placed above the crest of the alveolar bone, is denoted as the neck. The surface of the neck is usually highly polished. Implants may be classified as one- or two-piece implants (**Figure 5**):

One-piece implant: consists of an implant body and abutment made as a single solid unit. Thus, the screw joint between implant body and the abutment is eliminated. It is used with the one-stage implant placement protocol (**Figure 5a**).

Two-piece implant: consists of an abutment that is attached to the implant body through a screw joint (**Figures 5b** and **c**). This is the most commonly used implant type. It is used with the one- and two-stage implant placement method.

Several factors should be considered when an implant is chosen (**Table 1**). These factors are:

Implant length: longer implants have a higher initial stability compared with shorter implants as they are in more contact with the surrounding bone. The selected length is determined by several factors such as the quantity and quality of bone. If the implant length is increased by three millimetres, there will be an increase in bone to implant contact by about 20%.⁴⁹

It is reasonable to mention that earlier publications on implant length have revealed that short implants had a higher failure rate than long ones. This trend was attributed to the smooth surface implant, the surgical preparation and the poor quality of bone, rather than to the

implant length itself. As implant technology and surgical approaches improved, recently published studies have indicated that survival rates of short and long implants are comparable.⁵⁰

Implant diameter: the selection of an implant with a suitable diameter is governed by the bucco-lingual and mesio-distal dimensions of the edentulous space. It is also determined by bone quality and quantity in the region to be restored. For instance, when the quality of bone is poor, the selected implant must be wide enough. When the height of the available bone is limited, a short and wide implant may be an alternative.⁵⁰ Moreover, the implant should be wide enough to avoid its fracture under loading. It is important to remember that in order to achieve a good outcome, the roots of the adjacent teeth should be protected. Furthermore, any additional bone resorption should not expose the implant body and the interproximal bone should be capable of maintaining the height of the gingival papilla.

The use of a wide implant allows building up of the optimal restorative emergence profile and reduces the stresses on the retained screws. The available bone should be adequate to accommodate this implant. Wide implants are also suitable when an implant is installed immediately after tooth extraction. Wide and short implants may be considered when the bone height is limited by some anatomical structure to avoid surgical interventions such as ridge augmentation,

Table 1: Factors that should be considered when an implant is selected and their indications.

1. **Implant length:** a long implant should be considered whenever the condition permits.
2. **Implant diameter:** ideally, the implant should be of approximately the same diameter as the tooth it is replacing.
 - a. **Narrow implant:**
 - i. used to replace maxillary lateral incisors or mandibular incisors;
 - ii. limited edentulous space;
 - iii. limited ridge width (to avoid ridge augmentation surgery);
 - iv. when it is not possible to achieve good emergence profile with a wide implant body; and,
 - v. converging adjacent tooth roots.
 - b. **Wide implant:**
 - i. limited ridge height with adequate bucco-lingual width; and,
 - ii. immediate implant placement (after tooth extraction).
3. **Tapered implant:**
 - a. in type IV bone, where primary stability is difficult to achieve;
 - b. narrow or concave bone;
 - c. converging adjacent tooth roots; and,
 - d. immediate implant placement (after tooth extraction).

sinus lifting or nerve transposition.⁴⁹ It may also be advantageous to use a wide implant when the bucco-lingual width permits, as in the molar region, to reduce the stress on the retained screws. It may also enable the clinician to use a single implant instead of two. However, Ivanoff and associates³⁸ reported a higher failure rate (18%) for the 5mm diameter implants when compared with 5% and 3% for 3.75mm and 4mm diameters, respectively. This may be due to the fact that wide-diameter implants were frequently used in clinical situations that were not ideal for the use of the standard implants, or when initial implant stability is not achievable with the standard implant, such as when bone quality is poor.³⁸

The use of an implant with a wide platform, when the bucco-lingual bone width is limited, may cause an exposure of the coronal portion of the implant and consequently gingival recession and decrease in the height of the papilla. So an implant with a smaller diameter may be a solution for this problem. Small-diameter implants are indicated in specific clinical situations, for example where there is a reduced inter-radicular bone or a thin alveolar crest, and for the replacement of teeth with small cervical diameters.⁵¹ However, the use of small-diameter implants may be associated with biomechanical risk factors that should be evaluated before the use of such implants. Otherwise, alternative treatment options should be sought.

Taper

Tapered implants are indicated for use with immediate implant placement protocol after tooth extraction, as well as when the quality of bone is not good enough, i.e., type IV, as primary stability is not easy to achieve.⁵² The use of tapered implants results in lateral compression of bone and increased stiffness of the interfacial bone, which is reported to increase the implant primary stability.⁵³

Tapered implants are also used to avoid damage of converging roots of adjacent teeth that reduce the space available for placement of a parallel-sided implant. Likewise, they can be used in concave bone in which the use of the normal implants may result in implant exposure.⁴⁹

Implant selection

There are a variety of dental implant systems available in the market worldwide, but only a few brands with an ADA seal of approval. Among these are Nobel Biocare, Straumann, Astratech, BioHorizon, Intralock, Bicon, Biomet 3i, and Zimmer. Although they differ in patented technology, materials, and historical case success rates, they are all based on the same basic concepts.

The selection of a dental implant for a specific situation, particularly in the aesthetic area, is challenging for the dentist. Thus, a careful selection of the prospective implant is important to avoid an unexpected outcome. This requires a comprehensive investigation that ensures the best possible result. The edentulous area should be viewed in three dimensions: mesio-distal, bucco-lingual, and crono-apical. Also, the mesio-distal dimension of the edentulous space should be considered as two interrelated spaces (restorative and inter-radicular). The restorative space extends between the two adjacent teeth and should accommodate the prospective restoration. The inter-radicular



FIGURE 6: The cover screw (a) and the healing abutment (b).

space is located between the roots of the two adjacent teeth and will hold the implant body. The mesio-distal width of the restorative space depends on the width of the prospective restoration. The width of the roots of the teeth is usually estimated at 2mm apical to the cemento-enamel junction and according to this dimension the implant with a suitable diameter will be selected. In ideal situations the selected implant should have a diameter that approximates the diameter of the tooth being replaced. When the apico-coronal position of the implant is considered, the implant platform should be placed at approximately 2mm apical to the mid-labial gingival margin of the adjacent teeth. Thus an optimal emergence profile of the restoration will be achievable and the biologic width will be maintained.

It has been recommended that the implant should be placed at least 1.5mm mesio-distally from the root of the adjacent tooth with a minimum bone thickness of 1mm buccally and lingually. Therefore, a minimum mesio-distal inter-radicular space required to place an implant of 4mm would be 7mm or more. The bucco-lingual width of this edentulous space should not be less than 6mm to get at least 1mm of bone surrounding the implant. The facial bone height as well as width is important to maintain the peri-implant bone level at its optimal position. The inter-proximal bone height of the adjacent teeth is very important to maintain the height of the peri-implant papilla even in cases of bone resorption close to the implant surface. So encroachment on this bone by the implant platform will lead to inter-proximal bone resorption, which drastically leads to the reduction in the height of the papilla.

Cover screw

This is also known as a sealing screw. It is a part of the implant system that is screwed and attached to the implant platform during the healing stage after implant placement, thus preventing tissue growth into the implant. It is placed after the implant is inserted into the osteotomy that was prepared to receive the implant body (Figure 6a). The cover screw has a low profile in order to facilitate the suturing procedure and to allow approximating the two edges of the cut mucosa without excessive tension, which may deteriorate and preclude the healing.⁵⁴ The diameter of the cover screw is usually of similar dimension or may be slightly larger than the implant. The latter

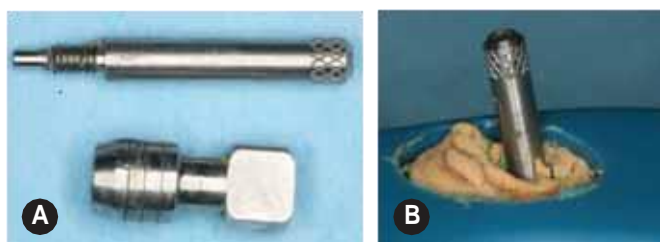


FIGURE 7: The impression of the implant platform using the pick-up method: the impression coping and the central screw used to fix the transfer coping to the implant (a). The screw is protruding through the tray to facilitate removal of the impression from the mouth (b).



FIGURE 8: The implant analogue.

is used to prevent formation of bone over the top surface of the cover screw, which has been reported to occur and may make removal of the screw troublesome. Bone is also difficult to remove without damaging the implant platform. The cover screw is screwed into the implant using a light finger force (5-10Ncm) and a screwdriver.

It is important to ensure that it is fully seated and no gap is left between the platform and the cover screw, which should remain *in situ* until it is removed in the second stage of surgery.

Early exposure of the cover screw and the breakdown of the peri-implant soft tissue may accelerate early peri-implant crestal bone resorption.⁵⁴

Healing abutment

This is also known as a sulcus former. It is attached to the implant body via a screw and both the abutment and the screw form one single unit. In the second surgery stage, the cover screw is removed and replaced with this abutment. The healing abutment has a dome-shaped superior surface. It comes in different lengths, from which the surgeon chooses. When it is attached to the implant platform, it should be projecting into the oral cavity (**Figure 6b**). The healing abutment is then replaced with a provisional or a final restoration.

The restorative components and procedure

The technique used to fabricate the implant-retained restoration usually requires an intra-oral impression of the abutment or the implant platform using conventional impression materials. Final impression, an impression of the opposing dental arch, an inter-occlusal record and a transfer-bow (face-bow) record are all sent to a dental laboratory, where the final restoration will be fabricated.^{36,49}

Impression techniques

The most common impression techniques used in the construction of single implant-supported restorations may be classified into two main headings:

impression of the implant platform:

- a pick-up method [an open-tray];
 - a transfer method [a closed-tray]; and,
- impression of the abutment.

Impression of the implant platform using either a pick-up or a transfer coping impression technique (**Figure 7**).

In both methods the impression coping must fit snugly into the implant platform, which should be verified using an intra-oral peri-apical radiograph and/or an audible and tactile 'click' feature that is incorporated into some implant systems to confirm the accuracy of the fit between the implant and the impression coping.

In the pick-up impression method (also known as the open tray), a perforated tray is used and the coping is secured to the implant body by a central screw. The screw should be protruding through the hole that the clinician makes in the roof of the tray when the impression is being made to enable the clinician to take the impression and the coping from the mouth at the same time when the impression material has set (**Figure 7b**). The coping is detached from the implant platform before removing the tray from the mouth.^{36,49}

When the transfer coping is used, the impression is first removed from the mouth while the coping remains attached to the implant. The coping is then removed and replaced in its imprint within the impression. The coping usually has a flat side or an undercut, which allows the dentist to place it in its proper position within the impression imprint. This technique is also known as the closed tray technique. The implant analogue (**Figure 8**) will then be attached to the coping surface. This method is suitable when mouth opening is limited. The impression can be removed from the mouth easily if the patient cannot tolerate it. However, the replacement of the copings into their actual position in the impression is not always precise.

Second impression technique

In the second impression technique, the impression of the abutment is made using a manufacturer-made impression coping, which fits the abutment. This technique is frequently used with a ready-made prefabricated abutment.

Laboratory analogue

The laboratory analogue is the part of the implant system that allows the dental technician to build up the restoration. Thus, it may either be an implant or abutment analogue.

The implant analogue is used when the impression of the implant

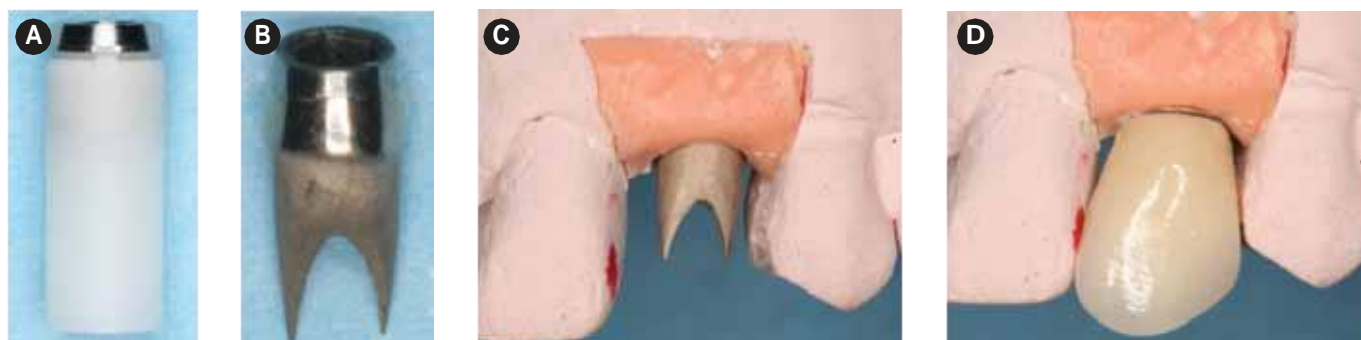

FIGURE 9: UCLA plastic pattern abutment with a machined interface before casting (a), and after modification and casting (b). The abutment is attached to the implant analogue on the cast (c) and the final restoration (porcelain fused to metal) (d).

platform was made (Figure 8), while the abutment analogue is used when the impression of the abutment itself was taken. The latter analogue is made to represent the exact configuration of the abutment.

In the laboratory, the implant or abutment analogue is attached to the impression coping and a soft-tissue cast is then made. The rest of the impression is made in dental stone in the usual way. The soft-tissue cast protects the peri-implant soft-tissue details, which are lost if they are made of stone as they will be trimmed away. The peri-implant soft-tissue details are required in order to accurately contour the final restoration. The methods by which the restorations are attached to the abutment are discussed later.

Abutments used for single implant restorations

The abutment is a part of the implant system that will accommodate the prospective restoration. They may be classified as follows:^{55,56}

A. Custom-made abutments

These abutments consist of a plastic/wax pattern with/without a metal-machined interface ring. The metal-machined interface ensures a precise fit with the implant platform (Figures 9a and 9b). The implant level impression is taken in the usual way.⁵⁶ In the laboratory the abutment plastic pattern is attached to the implant analogue on a working cast (Figure 9c). The plastic pattern is cut to the required form, shape and angle, then cast in metal alloy in a similar fashion to the conventional lost-wax technique. The restoration that fits the abutment is then fabricated (Figure 9d).

Custom-made abutments suit almost any clinical situation, regardless of whether the implant body is in the correct position or not, because they can be reduced as well as added to. UCLA plastic patterns are an example of these types of abutments (Figure 9a).

B. Ready-made (pre-machined) non-modifiable metal abutments

These abutments can be used without modification so that an abutment that is suitable for the specific clinical condition is selected and attached to the implant body. A manufacturer-made impression

coping is used in making the abutment impression.⁵⁵ These abutments can be temporised using the clinical resources available as in the conventional crown and bridge procedures.

C. Ready-made (pre-machined) modifiable metal abutments

These types of abutments are ready-made metal abutments but can be adjusted and shaped to meet a specific clinical situation. These abutments can be prepared and modified intra-orally and/or extra-orally on a master cast. Reshaping and adjusting the abutment may be time consuming.⁵⁵ They are not suitable for many clinical situations, such as when the implant is severely angulated and a major alteration is required.

D. All-ceramic abutments

This, as the name indicates, is made of ceramic and is used when aesthetics are of paramount importance. In general, all ceramic abutments are available in ready-made or customisable forms such as alumina and zirconia abutments.^{57,58} They are recommended for use in single tooth crown restorations (Figure 10). Furthermore, all-ceramic abutments may also be indicated in cases of thin biotype gingiva so the bluish colour of the gingival tissue, which may occur with the metal abutments, is avoided.

E. CAD/CAM milled abutments

CAD/CAM milled abutments are made from a block of titanium or ceramic. An implant platform level impression may be required depending on the manufacturers.^{59,60} Commonly, the implant platform impression is made and a working cast is fabricated. The cast is then scanned optically to generate exact 3D images of the region. The information is sent to the milling machine to form the morphologically correct abutment from a block of titanium alloy.

CAD/CAM technology allows elimination of certain factors such as inferior accuracy of casting procedures that negatively affect the long-term success of the restorations. So the CAD/CAM milled abutments are more precise than those created using the traditional casting technique. They also have no porosity.

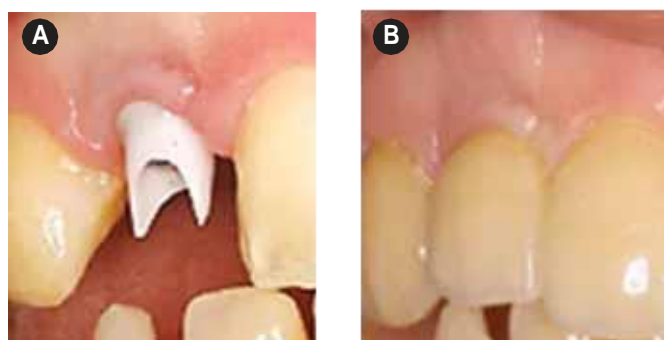


FIGURE 10: Zirconium abutment: after attachment to the implant (a); and, after cementation of the restoration (b) (courtesy of the Division of Restorative Dentistry and Periodontology, Dublin Dental University Hospital).

The CAD/CAM technique seems promising and may replace the conventional techniques for implants in the near future. However, the use of the CAD/CAM milled abutments is expensive, which may preclude their wide use at present.

Restoration

Implant-retained restorations may be divided into two types according to the method by which they are attached to the implant: screw- and cement-retained implant restorations. In the screw-retained implant restorations, the restoration is attached to the implant directly or to the abutment, while in the cement-retained ones, a cementing media is used to retain the restoration on the abutment.⁶¹

Cement-retained restoration

The cement-retained restoration can be used with minimum inter-occlusal restorative space and a restricted mouth opening is less problematic than with the use of the screw-retained restorations. It is suitable to use even when the implant angulation is not optimal as the restoration could still have good aesthetics.^{56,61,62} A restoration with an ideal occlusal morphology can be created in the normal way as in conventional restorations. The materials and techniques used for the fabrication of conventional restorations can be used with the cement-retained restoration. It may be possible to retrieve them if weak cements were used, i.e., soft provisional cement; otherwise, restorations have to be cut in order to remove them.

However, the use of cement-retained restorations is associated with difficulty in removing the cement and the inferiority of margin adaptation between the restoration and the abutment, which may result in soft tissue problems.^{56,61}

Screw-retained restorations

Screw-retained restorations usually consist of an abutment and a restoration as a single solid unit, which is attached to the implant body through a screw.^{56,61,62}

They can be removed and/or replaced without damage or the need

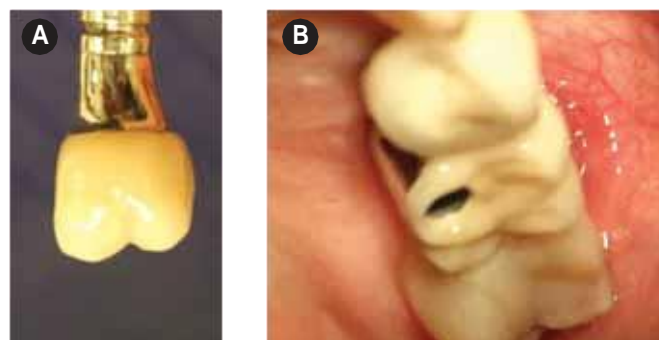


FIGURE 11: A screw-retained restoration; the abutment and the restoration are one integral part (a). A clinical picture; the screw hole can be seen in the occlusal surface of the restoration (b). This may interfere with the creation of the required occlusal morphology.

for a new restoration. The adaptation between the restoration and the underlying implant is significantly better than that in the case of its cement-retained counterpart. However, the implant should be placed in its optimal angulation to avoid interference with aesthetics. Furthermore, the screw hole in the posterior region may interfere with the creation of an ideal occlusal morphology (**Figure 11**). Nevertheless, clinical experience indicates that the hole within the abutment should be adequately wide to accommodate the retained screw without impinging on the axial walls of the hole, allowing screwing and torquing of the retained screw fully.

Screw-retained restorations are not suitable to use when mouth opening is limited, as the mouth opening should be adequate for the use of the different tools required for screwing and torquing the screws.

Conclusion

Dental implantology has become one of the branches that dominates the dental field. There is an extensive market of dental implant systems available worldwide. The two-piece implants have well-documented long-term success and survival rates. Implant selection is governed by many factors, which may not necessarily be under the clinician's control. Examples of this are the available bone height and width, the mesio-distal dimension of the edentulous spaces, the relationship between the roots of adjacent teeth, and the soft tissue phenotype.

The implementation of one of the loading protocols should be decided during the treatment planning process and after all investigations have been studied in depth to avoid disappointment and unexpected results.

Several abutment types are available and it is not possible to identify an abutment that is considered ideal for all clinical situations, as it may be suitable for use in one clinical situation but not for another. Selection of an abutment is governed by several factors such as aesthetics, implant angle and the available facilities, as well as the operator/laboratory technician's preference. Furthermore, custom-made abutments are easy to use, cheaper, and can be adjusted and modified as required. Also, the laboratory procedure is similar to the

conventional crown and bridge procedure. Yet, one disadvantage is that it is made of metal and in many clinical situations, such as when a high aesthetic demand is required, an optimal result may be difficult to achieve. The use of CAD/CAM abutments seems promising and is more likely to be widely used in the future. They are expensive; however, they have a potential of shortening the laboratory procedure and minimising human error, which in turn saves time.

Regarding restorations, the cement-retained method is a flexible technique suitable for most clinical situations. The cement-retained restoration is difficult to retrieve as the restoration has to be cut and a new one made. The materials and techniques used for the fabrication of conventional restorations can be used with the cement-retained restoration.

The screw-retained restoration has some advantages, such as retrieveability and good adaptation between the restoration and the implant platform. It also has some disadvantages, which have been mentioned previously in this paper.

We would like to thank Mrs Rosaleen Glackin, Division 2, Dublin Dental University Hospital, Dublin, Ireland, for her help.

References

1. Zupnik, J., Kim, S.-W., Ravens, D., Karimbux, N., Guze K. Factors associated with dental implant survival: a 4-year retrospective analysis. *Journal of Periodontology* 2011; 82: 1390-1395.
2. Albrektsson, T., Brånemark, P.-I., Hansson, H.A., Lindstrom, J. Osseointegrated titanium implants. Requirements for ensuring a long-lasting, direct bone-to-implant anchorage in man. *Acta Orthopaedica Scandinavica* 1981; 52: 155-170.
3. Garetto, L.P., Chen, J., Parr, J.A., Roberts, W.E. Remodelling dynamics of bone supporting rigidly fixed titanium implants: a histomorphometric comparison in four species including humans. *Implant Dentistry* 1995; 4: 235-243.
4. Albrektsson, T., Isidor, F. Consensus report of session IV. In: Lang, N.P., Karring, T. Proceedings of the First European workshop on Periodontology. Quintessence Publishing Co.: London; 1994: 365-369.
5. Brånemark, P.-I. Osseointegration and its experimental studies. *Journal of Prosthetic Dentistry* 1983; 50: 399-410.
6. Sennerby, L., Ericson, L.E., Thomsen, P., Lekholm, U., Astrand, P. Structure of the bone-titanium interface in retrieved clinical oral implants. *Clinical Oral Implants Research* 1991; 2: 103-111.
7. Frost, H.M. Wolf's law and bone's structural adaptations to mechanical usage: an overview for clinicians. *The Angle Orthodontist* 1994; 64: 175-188.
8. Huiskes, R., Ruimerman, R., van Lenthe, G.H., Janssen, J.D. Effects of mechanical forces on maintenance and adaptation of form in trabecular bone. *Nature* 2000; 405: 704-706.
9. Mosley, J.R. Osteoporosis and bone functional adaptation: mechanobiological regulation of bone architecture in growing and adult bone, a review. *Journal of Rehabilitation Research and Development* 2000; 37: 189-199.
10. Isidor, F. Loss of osseointegration caused by occlusal load of oral implants. A clinical and radiographic study in monkeys. *Clinical Oral Implants Research* 1996; 7: 143-152.
11. Warreth, A., Polyzois, I., Lee, C.T., Claffey, N. Generation of microdamage around endosseous implants. *Clinical Oral Implants Research* 2009; 2: 1300-1306.
12. Buser, D., Weber, H.P., Donath, K., Fiorellini, J.P., Paquette, D.W., Williams, R.C. Soft tissue reactions to non-submerged unloaded titanium implants in beagle dogs. *Journal of Periodontology* 1992; 63: 225-235.
13. Abrahamsson, I., Berglundh, T., Glantz, P.O., Lindhe, J. The mucosal attachment at different abutments. An experimental study in dogs. *Journal of Clinical Periodontology* 1998; 25: 721-727.
14. Ericsson, I., Randow, K., Nilner, K., Petersson, A. Some clinical and radiographical features of submerged and non-submerged titanium implants. A 5-year follow-up study. *Clinical Oral Implants Research* 1997; 8: 422-426.
15. Esposito, M., Grusovin, M.G., Polyzos, I.P., Felice, P., Worthington, H.V. Timing of implant placement after tooth extraction: immediate, immediate-delayed or delayed implants? A Cochrane systematic review. *European Journal of Implantology* 2010; 3: 189-205.
16. Kesting, M.R., Thurmüller, P., Ebsen, M., Wolff, K.D. Severe osteomyelitis following immediate placement of a dental implant. *The International Journal of Oral and Maxillofacial Implants* 2008; 23: 137-142.
17. Equivel-Upshaw, J. Dental implants. In: Anusavice, K.J. *Phillips Science of Dental Materials* (11th ed.). Philadelphia: WB Saunders; 2003: 759-781.
18. Sykaras, N., Iacopino, A.M., Marker, V.A., Triplett, R.G., Woody, R.D. Implant materials, designs, and surface topographies: their effect on osseointegration. A literature review. *International Journal of Oral and Maxillofacial Implants* 2000; 15: 675-690.
19. Thomas, K.A. Hydroxyapatite coatings. *Orthopaedics* 1994; 17: 267-278.
20. Weinlaender, M., Beumer, J. 3rd, Kenney, E.B., Lekovic, V., Holmes, R., Moy, P.K., et al. Histomorphometric and fluorescence microscopic evaluation of interfacial bone healing around 3 different dental implants before and after radiation therapy. *International Journal of Oral and Maxillofacial Implants* 2006; 21: 212-224.
21. Wie, H., Herø, H., Solheim, T. Hot isostatic pressing-processed hydroxyapatite-coated titanium implants: light microscopic and scanning electron microscopy investigations. *International Journal of Oral and Maxillofacial Implants* 1998; 13: 837-844.
22. Gross, K.A., Brendt, C.C., Iacono, V.J. Variability of hydroxyapatite-coated dental implants. *International Journal of Oral and Maxillofacial Implants* 1998; 13: 601-610.
23. Martinez, H., Davarpanah, M., Missika, P., Celletti, R., Lazzara, R. Optimal implant stabilisation in low density bone. *Clinical Oral Implants Research* 2001; 12: 423-432.
24. Gotfredsen, K., Nimb, L., Hjørting-Hansen, E., Jensen, J.S., Holmén A. Histomorphometric and removal torque analysis for TiO₂-blasted titanium implants. An experimental study on dogs. *Clinical Oral Implants Research* 2002; 3: 77-84.
25. Misch, C.E., Qu, M., Bidez, M.W. Mechanical properties of trabecular bone in the human mandible: implications for dental implant treatment planning and surgical placement. *Journal of Oral and Maxillofacial Surgery* 1999; 57: 700-706.

26. Todd, J., Misch, C.E., Bidez, M.W., Nulluri, P. Functional surface area: thread-form parameter optimisation for implant body design. *Compendium special issue* 1998; 19 (3): 4-10.
27. Klokkevold, P.R., Johnson, P., Dadgostari, S., Caputo, A., Davies, J.E., Nishimura, R.D. Early endosseous integration enhanced by dual acid etching of titanium: a torque removal study in the rabbit femur. *Clinical Oral Implants Research* 2001; 12: 350-357.
28. Wong, M., Eulenberger, J., Schenk, R., Hunziker, E. Effects of surface topology on the osseointegration of implant in trabecular bone. *Journal of Biomedical Materials Research* 1995; 29: 1567-1575.
29. Lazzara, R.J., Testori, T., Trisi, P., Porter, S.S., Weinstein, R.L. A human histologic analysis of osseotite and machined surface using implants with two opposing surfaces. *International Journal of Periodontics and Restorative Dentistry* 1999; 19: 117-129.
30. Tehemar, S.H. Factors affecting heat generation during implant site preparation: a review of biologic observations and future considerations. *International Journal of Oral and Maxillofacial Implants* 1999; 14: 127-136.
31. Eriksson, A.R., Albrektsson, T. Temperature threshold levels for heat-induced bone tissue injury: a vital-microscopic study in the rabbit. *Journal of Prosthetic Dentistry* 1983; 50: 101-107.
32. Eriksson, R.A., Albrektsson, T. The effect of heat on bone regeneration: an experimental study in the rabbit using the bone growth chamber. *Journal of Oral and Maxillofacial Surgery* 1984; 42: 705-711.
33. Matthews, L., Hirsch, C. Temperatures measured in human cortical bone when drilling. *Journal of Bone and Joint Surgery* 1972; 54: 297-308.
34. Cavallaro, J. Jr, Greenstein, B., Greenstein, G. Clinical methodologies for achieving primary dental implant stability: the effects of alveolar bone density. *Journal of the American Dental Association* 2009; 140: 1366-1372.
35. Watzek, G., Gruber, R. Morphologic and cellular parameters of bone quality. *Applied Osseointegration Research* 2002; 3: 3-8.
36. Drago, C. *Implant Restorations: A Step-by-Step Guide (2nd ed.)*. Blackwell: Munksgaard; 2007.
37. Sennerby, L., Roos, J. Surgical determinants of clinical success of osseointegrated oral implants: a review of the literature. *The International Journal of Prosthodontics* 1998; 11: 408-420.
38. Ivanoff, C.J., Gröndahl, K., Sennerby, L., Bergström, C., Lekholm, U. Influence of variations in implant diameters: a 3- to 5-year retrospective clinical report. *The International Journal of Oral Maxillofacial Implants* 1999; 14: 173-180.
39. Kiuru, M. Magnetic resonance imaging of fatigue bone stress injury. Academic Dissertation, Helsinki University Central Hospital, Department of Diagnostic Radiology, Helsinki, Finland, 2002.
40. Lekholm, U., Zarb, G.A. Patient selection and preparation. In: Brånemark, P., Zarb, G., Albrektsson, T. *Tissue-Integrated Prostheses. Osseointegration in Clinical Dentistry (1st ed.)*. Quintessence Publishing Co.; 1985: 195-205.
41. Jaffin, R.A., Berman, C.L. The excessive loss of Branemark fixtures in type IV bone: a 5-year analysis. *Journal of Periodontology* 1991; 62: 2-4.
42. Esposito, M., Grusovin, M.G., Coulthard, P., Worthington, H.V. Different loading strategies of dental implants: a Cochrane systematic review of randomised controlled clinical trials. *European Journal of Oral Implantology* 2008; 1: 259-276.
43. Weber, H.-P., Morton, D., Gallucci, G.O., Rocuzzo, M., Cordaro, L., Grütter, L. Consensus statements and recommended clinical procedures regarding loading protocols. *The International Journal of Oral and Maxillofacial Implants* 2009; 24: 180-183.
44. Adell, R., Lekholm, U., Rockler, B., Brånemark, P.I. A 15-year study of osseointegrated implants in the treatment of the edentulous jaw. *International Journal of Oral Surgery* 1981; 10: 387-416.
45. Maeda, Y., Satoh, T., Sogo, M. *In vitro* differences of stress concentrations for internal and external hex implant-abutment connections: a short communication. *Journal of Oral Rehabilitation* 2006; 33: 75-78.
46. McGlumphy, E.A., Mendel, D.A., Holloway, J.A. Implant screw mechanics. *Dental Clinics of North America* 1998; 42: 71-89.
47. Keating, K. Connecting abutments to dental implants: an engineer's perspective. *Irish Dentist* 2001; July: 43-46.
48. Binon, P.P. Implants and components: entering the new millennium. *The International Journal of Maxillofacial Implants* 2000; 15: 76-94.
49. Jacobs, S.H., O'Connell, B.C. *Dental Implant Restoration: Principles and Procedures (1st ed.)*. Quintessence Publishing; 2011.
50. Renouard, F., Nisand, D. Impact of implant length and diameter on survival rates. *Clinical Oral Implants Research* 2006; 17 (Suppl. 2): 35-51.
51. Davarpanah, M., Martinez, H., Tecuciana, J.-F., Celletti, R., Lazzara, R. Small-diameter implants: indications and contraindications. *Journal of Esthetic Dentistry* 2000; 12: 186-194.
52. Alves, C.C., Neves, M. Tapered implants: from indications to advantages. *The International Journal of Periodontics and Restorative Dentistry* 2009; 29: 161-167.
53. Sennerby, L. Implant integration and stability. In: Palacci, P. (ed.). *Aesthetic Implant Dentistry: Soft and Hard Tissue Management*. Quintessence Books, 2001.
54. Kim, T.H., Lee, D.W., Kim, C.K., Park, K.H., Moon, I.S. Influence of early cover screw exposure on crestal bone loss around implants: intraindividual comparison of bone level at exposed and non-exposed implants. *Journal of Periodontology* 2009; 80: 933-939.
55. Christensen, G.J. Selecting the best abutment for a single implant. *Journal of American Dental Association* 2008; 139: 484-487.
56. Warreth, A., Fesharaki, H., McConville, R., McReynolds, D. An introduction to single implant abutments. *Dental Update* 2013; 40: 7-17.
57. Kohal, R.-J., Att, W., Bächle, M., Butz, F. Ceramic abutments and ceramic oral implants. An update. *Periodontology* 2000 2008; 47: 224-243.
58. Watkin, A., Kerstein, R.B. Improving darkened anterior peri-implant tissue colour with zirconia custom implant abutments. *Compendium of Continuing Education in Dentistry* 2008; 29: 238-240.
59. Priest, G. Virtual-designed and computer-milled implant abutments. *Journal of Oral and Maxillofacial Surgery* 2005; 63 (Suppl. 2): 22-32.
60. Drago, C.J. Two new clinical/laboratory protocols for CAD/CAM implant restorations. *Journal of American Dental Association* 2006; 137: 794-800.
61. Newsome, P., Reaney, D., Owen, S. Screw- versus cement-retained crowns. *Irish Dentist* 2011; March: 22-25.
62. Hebel, K.S., Gajjar, R.C. Cement-retained versus screw-retained implant restorations: achieving optimal occlusion and aesthetics in implant dentistry. *Journal of Prosthetic Dentistry* 1997; 77: 28-35.